

Lack of Effect of Ammonium Glycyrrhizinate on the Morphology of Ovine Nasal Mucosa *in Vitro*

Patricia M. Reardon,¹ Doris A. Wall,^{2,4}
Timothy K. Hart,³ Philip L. Smith,² and
Caroline H. Gochoco²

Received May 19, 1992; accepted February 28, 1993

Glycyrrhetic acid derivatives are reported to be nasal absorption promoters (1). Effects of ammonium glycyrrhizinate (AMGZ) on the *in vitro* morphology of ovine nasal mucosa were therefore examined by light and electron microscopy. Nasal mucosa was stripped from the submucosa and mounted in Ussing chambers. Exposure of the apical surface to 2% ammonium glycyrrhizinate (24 mM) for 90 min caused no histopathological changes to the nasal epithelium. Epithelial integrity remained intact as evidenced by the continued presence of morphologically intact junctional complexes. No sloughing of the epithelial layer from the basement membrane was observed, and cilia and microvilli were not affected by treatment with AMGZ. The results indicate that short-term exposure *in vitro* to ammonium glycyrrhizinate caused no overt morphological damage to ovine nasal mucosa.

KEY WORDS: enhancer; nasal; morphology; ammonium glycyrrhizinate.

INTRODUCTION

Systemic delivery of therapeutic peptides and proteins via the nasal route is of pharmaceutical interest. In contrast to the oral route, nasally administered peptides and proteins bypass extensive degradation because of gastric pH, intestinal peptidases, and first-pass metabolism (2–5). However, use of the nasal route is currently limited to peptides of 10 amino acids or fewer, for which transport across the nasal epithelium is relatively rapid (3), while larger proteins, in general, show poor bioavailability via this route (4,6,7). Therefore absorption promoters (e.g., fusidic acid derivatives, fatty acids, or phospholipids) to improve bioavailability of therapeutic proteins and peptides have been investigated (8–11). Nasal absorption promoters may act, in part, by altering the structural integrity of the mucosal epithelium (12,13). Severe damage to epithelial cell membranes by many absorption enhancers may preclude their use in treatment of chronic diseases.

Wheatley *et al.* (13) described physiological and histo-

pathological damage to sheep nasal tissue following treatment *in vitro* with sodium deoxycholate. More recently, *in vivo* studies by Ennis *et al.* (9) utilized scanning electron microscopy (SEM) to evaluate changes in rat nasal mucosa after treatment with sodium deoxycholate, nonionic surfactants, and sodium tauro-24,25-dihydrofusidate. They demonstrated that acute exposure to some absorption promoters (e.g., sodium deoxycholate) is sufficient to cause extensive damage to the nasal epithelium, suggesting that such absorption enhancing agents may not be suitable for chronic use. However, the utility of both LM⁵ and SEM is limited to examination of gross changes histologically or in surface features. Neither is effective in evaluating more subtle alterations at the ultrastructural level such as disruption of intercellular junctions.

Glycyrrhetic acid and a number of its derivatives enhance the *in vivo* nasal absorption of insulin in rats (1); further, ammonium glycyrrhizinate (AMGZ), the ammonium salt of glycyrrhetic acid glycoside, increases the paracellular permeability of ovine nasal tissue to the low molecular weight diffusional markers, mannitol (MW 182 Da) and lucifer yellow (MW 521 Da), but not to a higher MW (873 Da) hydrophilic peptide (14). In this study, effect(s) of AMGZ on morphology of sheep nasal tissue were ascertained by LM, SEM, and TEM. The findings indicate little morphologic alteration of nasal tissue after treatment with this compound.

MATERIALS AND METHODS

Materials

Glutaraldehyde (Lot 93619), propylene oxide (Lot 94697), dodecenylsuccinic anhydride (Lot 00568), nadic methyl anhydride (Lot 400501), DMP-30 (Lot 400001), and Poly/bed 812 embedding media (Lot 400372) were purchased from Polysciences, Inc., Warrington, PA. Osmium tetroxide (Lot 910322) was purchased from Electron Microscopy Sciences, Fort Washington, PA. Except where indicated, all other compounds used in this study were purchased from Sigma Chemical Company, St. Louis, MO.

Tissue Preparation for Ussing Chambers

Ovine tissue was obtained locally and mounted in Ussing chambers (1.13-cm² exposed area) as described previously (13). Tissues were equilibrated for 60–120 min in 10 mL bicarbonate-buffered Ringer solution with 10 mM glucose in the serosal bath and 10 mM mannitol in the mucosal bath. Throughout the equilibration period, transepithelial potential difference with reference to the mucosal bathing solution and short-circuit current were measured using a current/voltage clamp (Physiologic Instruments VCC600, Houston, TX). Tissues were continuously short-circuited via electrodes at the distal ends of each half-chamber except for brief intervals (<10 sec) during which time the potential dif-

¹ Department of Pharmaceutical Chemistry, University of Kansas, Lawrence, Kansas.

² Department of Drug Delivery, SmithKline Beecham Pharmaceuticals, King of Prussia, Pennsylvania 19406.

³ Department of Toxicology, SmithKline Beecham Pharmaceuticals, King of Prussia, Pennsylvania 19406.

⁴ To whom correspondence should be addressed at Drug Delivery Department, UW-2111, SmithKline Beecham Pharmaceuticals, P.O. Box 1539, King of Prussia, Pennsylvania 19406-0939.

⁵ *Abbreviations used:* AMGZ, ammonium glycyrrhizinate; LM, light microscopy; SEM, scanning electron microscopy; TEM, transmission electron microscopy; PB, 0.1 M phosphate buffer, pH 7.4.

ference was measured. Transepithelial conductance was calculated as described previously (15).

Morphological Studies

Effects of AMGZ on ovine nasal mucosa were analyzed by light, scanning, and transmission electron microscopy. Ovine nasal mucosa was mounted in Ussing chambers as indicated above. After equilibration, tissues were incubated for 30 to 90 min in the absence or presence of 1 or 2% AMGZ. Chambers were then drained and thoroughly rinsed with ice-cold 0.1 M phosphate buffer, pH 7.4 (PB). Other control tissues were mounted in Ussing chambers, rinsed with PB, and immediately processed for microscopy to assess the effects of the Ussing chamber on mucosal morphology. Tissues were fixed with 2.5% glutaraldehyde in PB overnight at 4°C, then cut in 1-mm² pieces, rinsed thoroughly with PB, and postfixed in 1% osmium tetroxide in PB for 1 hr, followed by a PB washing. Tissues were dehydrated with ethanol, infiltrated with 50:50 Epon/propylene oxide mixture, and embedded in Epon (Poly/Bed 812; Polysciences, Fort Washington, PA). Thin sections were collected on copper grids and stained with uranyl acetate and lead citrate. Thick sections (0.7–1.0 μm) were stained with methylene blue and basic fuchsin. Samples for SEM were dehydrated in ethanol, dried in hexamethyldisilazane, and mounted on specimen stubs. Specimens were sputter-coated with 20 nm gold.

Tissue from six or seven different regions selected at random from each 1.13 cm² exposed area of mucosa was examined by LM for each protocol (controls and AMGZ-treated). SEM and TEM experiments were both performed twice, with tissue from different animals: at least three samples were examined for each treatment protocol in each experiment.

RESULTS

Preliminary work to determine effects of AMGZ on properties of ovine nasal mucosa indicated a reversible decrease in short-circuit current and tissue resistance with a corresponding selective increase in paracellular permeability of tissue as indicated by higher transepithelial flux rates of the low molecular weight markers mannitol (MW 182 Da) and lucifer yellow (MW 521 Da) but not of a hydrophilic hexapeptide (MW 873 Da) molecule (14). This study was designed to address whether such changes in electrical and transport properties of nasal mucosa correlate with alterations in structural integrity following treatment with AMGZ.

The nasal epithelium of humans and other mammalian species including sheep is comprised of four cell types: ciliated cells, which carry mucus toward the pharynx via movement of the cilia; goblet cells, which produce and replenish the mucus layer; basal cells which act as "replacement" cells; and nonciliated columnar cells which may function in fluid transport (16). Figures 1A and B are scanning electron micrographs, illustrating the appearance of the surface of ovine nasal mucosa fixed immediately after mounting in the Ussing chamber (control tissue). Mucosal appearance is similar to that described previously in a variety of species, including humans (17–19). Areas rich in ciliated cells are in-

terspersed with areas in which nonciliated cells predominate: a highly ciliated region is shown in Fig. 1A. Ducts of the submucosal glands open to the surface in regions which appear as depressions in the epithelial surface. Cilia and microvilli can be clearly distinguished at higher magnification in Fig. 1B. Figure 1C is a light micrograph of untreated control tissue, showing a cross section of the mucosa. The typical pseudostratified columnar epithelium contains basal cells, goblet cells with mucus granules, and ciliated epithelial cells.

Figures 2A and B are scanning electron micrographs of ovine nasal tissue treated with 2% AMGZ for 90 min. The overall morphology of the nasal mucosa is unaffected by exposure to the enhancer; no sloughing of cells is evident, and cilia and microvilli are abundant and undamaged. Regional variations in the density of cilia result in their having a more "matted" or "fused" appearance in some areas at lower magnification by SEM (compare Figs. 1A and 2A; Fig. 2A was taken from a region of the mucosa richer in ciliated cells). However, a more rigorous comparison of the morphology of AMGZ-treated and control cilia and microvilli at higher magnification by both SEM (Figs. 1B and 2B) and TEM (Fig. 3) shows no differences in fine structure resulting from AMGZ treatment. Figure 2C is a light micrograph of AMGZ-treated tissue, demonstrating the lack of gross structural damage after 2% AMGZ exposure. Some membrane "blebbing" was observed in these tissues (Fig. 2C) but is also seen in untreated controls (not shown), indicating that this occurs from incubation in Ussing chambers and is not a direct effect of AMGZ treatment.

Transmission electron microscopy confirmed that 2% AMGZ treatment caused little tissue damage. Figures 3A–D are micrographs of nasal tissue incubated in Ussing chambers without (A and B) or with 2% AMGZ (C and D) for 90 min after tissue equilibration. Although vacuolation of the cytoplasm (v in Figs. 3A and 3C) and blebbing of the apical surface (b in Fig. 3C) was seen in some cells, the overall morphological appearance did not differ between treatment and control groups. Cilia and microvilli are intact and junctional complexes appear normal at higher magnification (Figs. 3B and D) in both AMGZ treated and untreated tissues.

DISCUSSION

Criteria for evaluating toxicity to nasal epithelia *in vitro* or *in vivo* include ciliary motility, membrane perturbation, and tissue histopathology (9,10,20–23). Correlation between absorption enhancement and tissue damage is seen for systems utilizing bile salts, laurith-9, and acylcarnitines (20,24). For example, although sodium deoxycholate, a bile salt, increases the apparent bioavailability of insulin in humans (25,26), morphologic analysis of its effects on rat nasal tissue by SEM suggests that it acts by disrupting integrity of epithelial membranes (9). Such absorption-damage correlations may not be as straightforward for other enhancers, and less damaging agents are clearly needed.

The objective of this study was to examine the effects of exposure to AMGZ on morphology of the nasal mucosa. Previous *in vitro* studies to investigate its effect on transport and electrical properties of ovine nasal mucosa (14) demon-

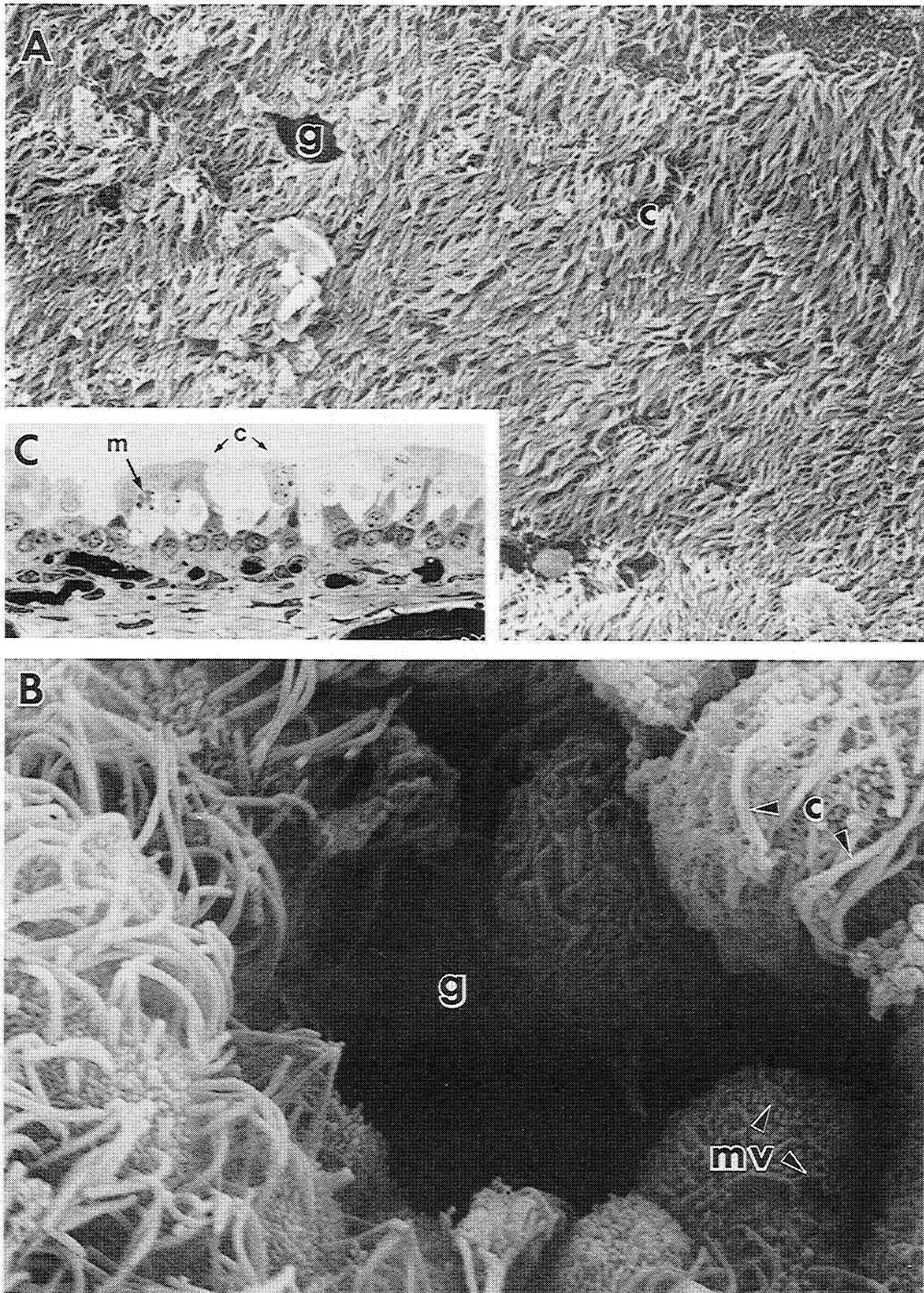


Fig. 1. Morphology of control ovine nasal mucosa. (A) Scanning electron micrograph (SEM) of untreated control nasal tissue fixed immediately after mounting in the Ussing chamber. Ciliated (c) cells predominate in the region shown here. The opening of a submucosal gland duct is apparent as a depression (g). (B) SEM at a higher magnification showing normal appearance of microvilli (mv) and cilia (c) at the apical surfaces of epithelial cells. A gland duct opening is seen at g. (C) Light micrograph of control tissue, illustrating the typical structure of pseudostratified columnar epithelium of nasal mucosa. Cilia (c), mucus droplets (m) within goblet cells, and small rounded basal cells are seen within the mucosal layer. (A) 800 \times , (B) 6400 \times , and (C) 480 \times ; reduced to 92% for reproduction.

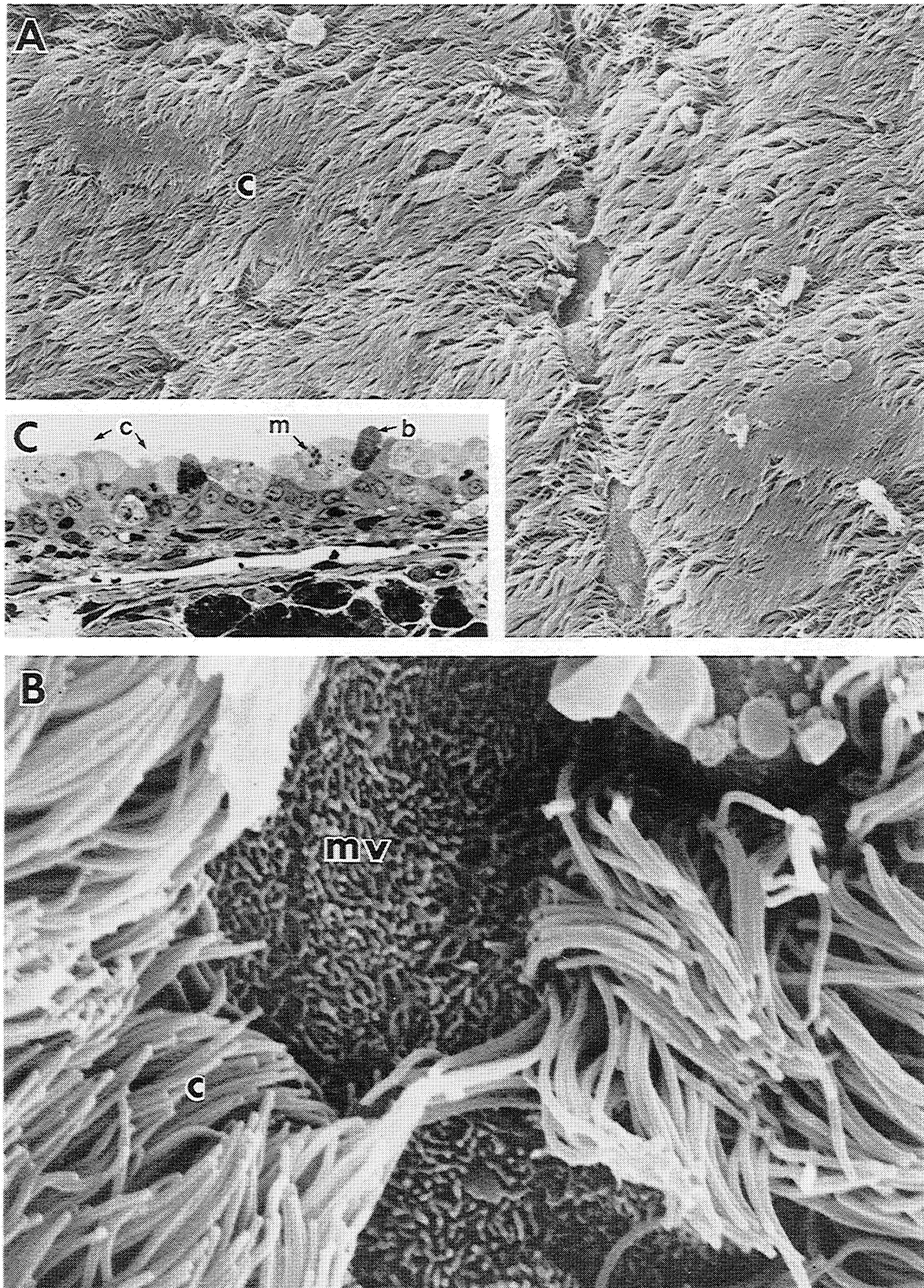


Fig. 2. Morphology of ovine nasal mucosa treated with 2% AMGZ for 90 min. (A) SEM of AMGZ-treated tissue. AMGZ exposure did not affect the morphology of nasal epithelium. Ciliated cells remained abundant and the overall appearance of cilia (c) was unchanged after AMGZ treatment. (B) Higher magnification SEM showing that AMGZ exposure had no effect on appearance of the cilia (c) or microvilli (mv) on epithelial cell surfaces. (C) Light micrograph of AMGZ-treated tissue, showing maintenance of structural integrity of mucosa exposed to the enhancer. No cell sloughing or damage to the submucosa is seen. Goblet cells containing mucus droplets (m) and cilia (c) are comparable to those seen in control tissue (compare with Fig. 1C). Some cells show blebbing of the apical surface (b). (A) 800 \times , (B) 8000 \times , and (C) 480 \times ; reduced to 92% for reproduction.

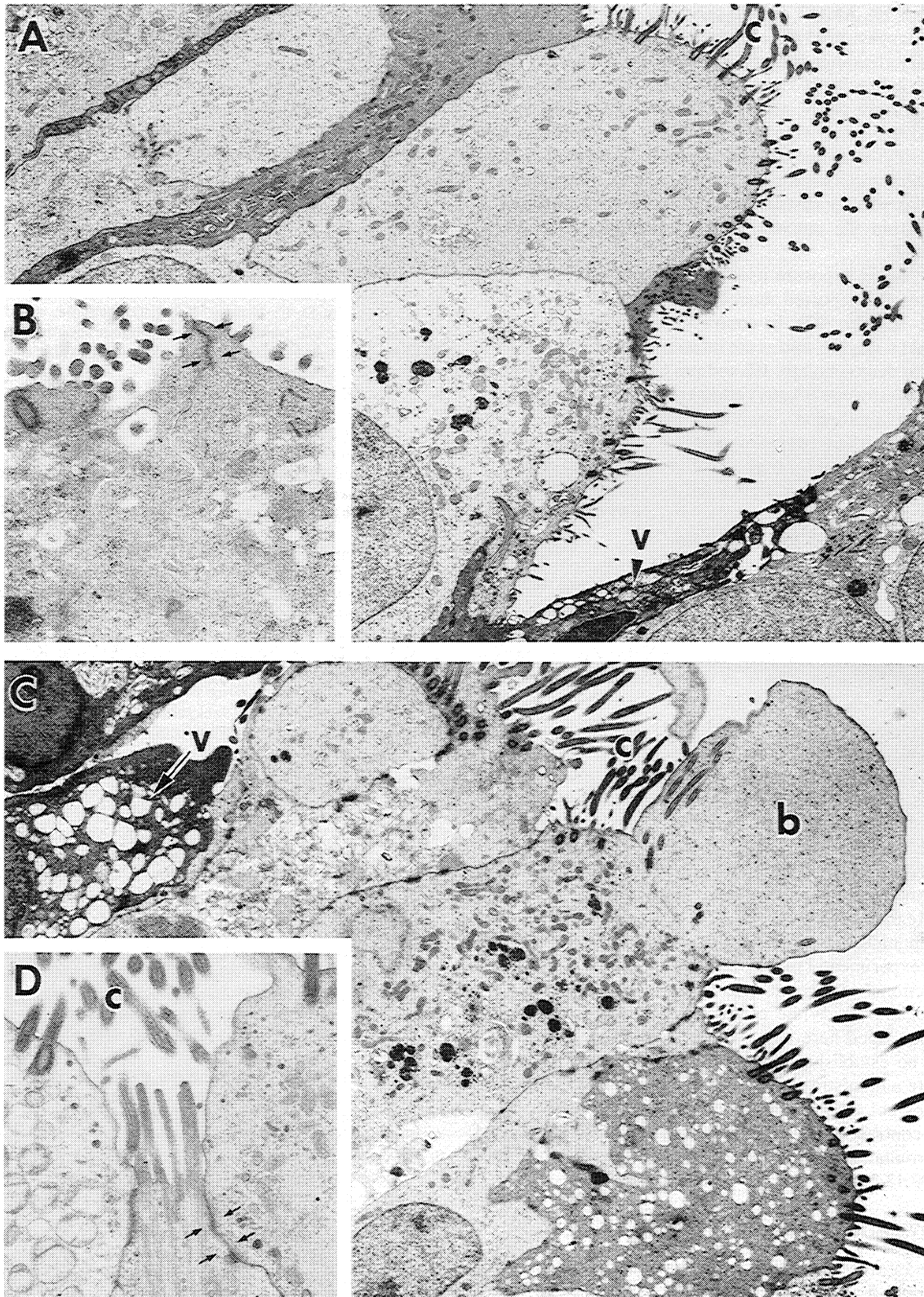


Fig. 3. Transmission electron micrographs of treated control and 2% AMGZ-treated ovine nasal mucosa. (A) Treated control tissue, showing vacuolation of the cytoplasm in some cells (v) interspersed with cells of normal appearance. Abundant cilia (c) protrude from the apical surface of many epithelial cells. (B) Junctional complexes (indicated by arrows) are normal in appearance in treated control tissue. (C) Two percent AMGZ-treated tissue, showing similarity in appearance with control samples. As seen in controls, some cells are vacuolated (v), but cilia and junctions appear intact. One cell in this field has an apical bleb (b). (D) Appearance of junctional complexes (arrows) is identical to that of control tissue. (A) 5220 \times , (B) 15,000 \times , (C) 5220 \times , and (D) 10,800 \times ; reduced to 92% for reproduction.

strated that 2% AMGZ caused subtle and reversible physiological changes. Analysis of the effect of 0.5–2% AMGZ on mucociliary clearance in frog palate mucosa *in vitro* revealed no effect, indicating a lack of ciliary toxicity (20). Results from the current study indicate that nasal tissue exposed to 2% AMGZ for up to 90 min showed no ultrastructural damage. Both cytoarchitectural features of the epithelial cells such as cilia, microvilli, tight junctions, and subcellular organelles, as well as distribution of ciliated and nonciliated regions within the mucosa were unaffected by treatment with AMGZ.

The 90-min exposure used in this study is greater than three times the reported mucociliary clearance time in humans (12–15 min) (27). In contrast, SEM analysis demonstrated that a single 5-min acute intranasal dosing of rats with 1% sodium deoxycholate, 1% sodium taurodeoxycholate, or 1% polyoxyethylene-9-lauryl ether caused extensive damage to the nasal epithelium, including partial or complete removal of the surface epithelial cells to expose the underlying basal cells and lamina propria, with thinning and fusion of remaining cilia (9). In addition, a diffuse sloughing of ciliated cells has also been demonstrated by SEM of frog palate treated with 1% sodium taurocholate (20).

The Ussing chamber technique has been used to study transepithelial transport, assess tissue viability and integrity, and determine metabolic capabilities of epithelial membranes (15,28,29) including the nasal mucosa (13,30). In the present study, comparison of the morphology of tissues incubated in Ussing chambers in the presence or absence of AMGZ shows no significant alteration of structural and cellular features of the nasal epithelium (Figs. 1–3). Although some apical membrane “blebbing” was observed in all tissues (both with and without AMGZ) after incubation in chambers, previous results (14) indicate that these tissues reestablish functional ion transport systems and have conductance values which remain consistently low (6.72 mS/cm²) over the course of several hours. These observations suggest that blebbing is not indicative of a loss in either tissue integrity or viability. Moreover, as paracellular transport of mannitol is maintained at a low and constant rate over the experimental time course (14), no gross alteration in tight junctional permeability results from tissue incubation in Ussing chambers. While correlations between the *in vitro* results described here and the effects of AMGZ *in vivo* remain to be established, the current data provide evidence that acute administration of AMGZ, over a 90-min time period, does not alter the morphology of sheep nasal epithelium, in contrast to severe damage reported for a number of other formulation components proposed as absorption promoters (9,13,20).

ACKNOWLEDGMENTS

The authors would like to express their appreciation to M. Madonna-Langan, A. Klinkner, M. Nichols, and Dr. R. Kirsh for their assistance in light and electron microscopy.

REFERENCES

- M. Mishima, S. Okada, Y. Wakita, and M. Nakano. Promotion of nasal absorption of insulin by glycyrrhetic acid derivatives. *I. J. Pharmacobio. Dyn.* 12:31–36 (1989).
- A. E. Pontiroli and G. Pozza. Intranasal drug delivery: Potential advantages and limitations from a clinical pharmacokinetic perspective. *Clin. Pharmacokin.* 17:299–307 (1989).
- A. E. Pontiroli and G. Pozza. Intranasal administration of peptide hormones: Factors affecting transmucosal absorption. *Diabetic Med.* 7:770–774 (1990).
- V. H. L. Lee. Protease inhibitors and penetration enhancers as approaches to modify peptide absorption. *J. Control. Release* 13:213–223 (1990).
- L. Illum. Nasal delivery of peptides and proteins. *Tibtech.* 9:284–289 (1991).
- C. McMartin, L. E. F. Hutchinson, R. Hyde, and G. E. Peters. Analysis of structural requirements for the absorption of drugs and macromolecules from the nasal cavity. *J. Pharm. Sci.* 76:535–540 (1987).
- K. S. E. Su, D. C. Howey, K. M. Campanale, and J. Q. Oeswein. Intranasal administration of human sodium insulin (HSI) in rats, dogs and humans: Absorption and possible mechanisms. *Diabetes* 35:A64 (1986).
- D. T. O'Hagan, H. Critchley, N. F. Farraj, A. Fisher, B. R. Johansen, S. S. Davis, and L. Illum. Nasal absorption enhancers for biosynthetic human growth hormone in rats. *Pharm. Res.* 7:772–776 (1990).
- R. D. Ennis, L. Borden, and W. A. Lee. The effects of permeation enhancers on the surface morphology of rat nasal mucosa: A scanning electron microscopy study. *Pharm. Res.* 7:468–475 (1990).
- P. Tengamnuay and A. K. Mitra. Bile salt-fatty acid mixed micelles as nasal absorption promoters of peptides. II. *In vivo* nasal absorption of insulin in rats and effects of mixed micelles on the morphological integrity of the nasal mucosa. *Pharm. Res.* 7:370–375 (1990).
- V. H. L. Lee, A. Yamamoto, and U. Bhaskar Kompella. Mucosal penetration enhancers of peptide and protein drug absorption. *Crit. Rev. Ther. Drug Carrier Syst.* 8:91–192 (1991).
- S. J. Hersey and R. T. Jackson. Effect of bile salts on nasal permeability *in vitro*. *J. Pharm. Sci.* 76:876–879 (1987).
- M. A. Wheatley, J. Dent, E. B. Wheelodon, and P. L. Smith. Nasal drug delivery: An *in vitro* characterization of transepithelial electrical properties and fluxes in the presence or absence of enhancers. *J. Control. Release* 8:167–177 (1988).
- P. M. Reardon, C. H. Gochoco, K. L. Audus, G. Wilson, and P. L. Smith. *In vitro* transport across ovine mucosa: Effects of ammonium glycyrrhizinate on electrical properties and permeability of growth hormone releasing peptide, mannitol, and lucifer yellow. *Pharm. Res.* 10:553–561 (1993).
- P. L. Smith and M. Field. *In vitro* secretory effect of trifluoperazine and other neuroleptics in rabbit and human small intestine. *Gastroenterology* 78:1545–1553 (1980).
- Y. W. Chien, K. S. E. Su, and S.-F. Chang. Nasal systemic drug delivery. In *Drugs Pharm. Sci. Vol. 39*, 1989.
- N. Mygind. *Nasal Allergy*, Blackwell Scientific, London, 1979, pp. 3–38.
- A. N. Fisher. Absorption across the nasal mucosa of animal species: Compounds applied and mechanisms involved. In G. G. Gibson (eds.), *Progress in Drug Metabolism*, Taylor and Francis, New York, 1990, pp. 87–145.
- J. A. Popp, N. A. Monteiro-Riviere, and J. T. Martin. Ultrastructure of the rat nasal mucosa. In C. S. Barrow (eds.), *Toxicology of the Nasal Passages*, Hemisphere, Washington, DC, 1986, pp. 37–49.
- P. C. Braga, G. Piatti, A. Bernini, and M. Dal Sasso. Topical tolerability of calcitonin nasal preparation, its excipients and sodium taurocholate studied by SEM and mucociliary transport velocity. *Drug Invest.* 4(1):40–46 (1992).
- E. L. LeCluyse, L. E. Appel, and S. C. Sutton. Relationship between drug absorption enhancing activity and membrane perturbing effects of acylcarnitines. *Pharm. Res.* 8:84–87 (1991).
- S. G. Chandler, L. Illum, and N. W. Thomas. Nasal absorption in the rat. A method to demonstrate the histological effects of nasal formulations. *Int. J. Pharm.* 70:19–27 (1991).
- W. A. J. J. Hermens, M. J. M. Deurloo, S. G. Romeyn, J. C.

- Verhoef, and F. W. H. M. Merkus. Nasal absorption enhancement of 17- β -estradiol by dimethyl- β -cyclodextrin in rabbits and rats. *Pharm. Res.* 7:500-503 (1990).
24. R. De Ponti and E. Lardini. Use of chemical enhancers for nasal drug delivery. *Drug Dev. Indust. Pharm.* 17:1419-1436 (1991).
 25. G. S. Gordon, A. C. Moses, R. D. Silver, J. S. Flier, and M. C. Carey. Nasal absorption of insulin: Enhancement by hydrophobic bile salts. *Proc. Natl. Acad. Sci. USA* 82:7419-7423 (1985).
 26. A. C. Moses, G. S. Gordon, M. C. Carey, and J. S. Flier. Insulin administered intranasally as an insulin-bile salt aerosol. *Diabetes* 32:1040-1047 (1983).
 27. I. Andersen and D. F. Proctor. Measurement of nasal mucociliary clearance. *Eur. J. Resp. Dis.* 64:37-40 (1983).
 28. J. H. Sellin and R. DeSoignie. Rabbit proximal colon: A distinct transport epithelium. *Am. J. Physiol.* 246:G603-G610 (1984).
 29. B. Matuszewska, G. G. Liversidge, F. Ryan, J. Dent, and P. L. Smith. *In vitro* study of intestinal absorption and metabolism of 8-L-arginine vasopressin and its analogues. *Int. J. Pharm.* 46:1110-1120 (1988).
 30. D. Cremaschi, C. Rossetti, M. T. Draghetti, C. Manzoni, and V. Aliverti. Active transport of polypeptides in rabbit respiratory nasal mucosa. *J. Control. Release* 13:319-320 (1990).